



DATE CLINICAL BACKGROUND & STUDY DETAILS

4.9.26

History: Recheck echo. Doing well at home. Chronic intermittent vomiting. History of CKD Stage 2 diagnosed after AKI 11/2019. Eating k/d dry and RC Renal D. No other medications.

PATIENT

Cricket Hepner

Current medications: None.

Sedation used: Not required to complete full diagnostic ultrasound.

Pertinent previous ultrasound results (11/2022 MML): UCM versus normal. Mild LAE. LA/AO: 1.5. Was on fluid therapy at that time.

STAT: Not requested.

SPECIES

Feline

Imaging performed by: Stephanie Warga RDCS, RVT.

BREED

DSH

SEX

MN

AGE

2.14.11

ECHOCARDIOGRAM FINDINGS

2D, m-mode, color flow and doppler imaging is available. The left ventricular wall is normal in dimension. There is a mildly hyperechoic endocardium consistent with mild fibrosis. The endocardium also appears mildly remodeled. The papillary muscles are normal in size and hyperechoic. The left atrium is normal in size. The right atrium is normal in size. The right ventricle appears normal. The mitral valve is normal in structure and mobility. No obvious valve regurgitation. Blood flow through both the LVOT and RVOT is normal in velocity. No pleural or pericardial effusion seen. No obvious cardiac tumors.

WEIGHT

14.7lbs

CARDIAC CHART

FELINE CARDIAC PARAMETERS	BODY WEIGHT (kg)	HR (BPM)	IVSd (cm) (Moise, Pipers)	LVIDd (cm) (Moise, Pipers)	LVWd (cm) (Moise, Pipers)	FS (%)	EF (%)
NORMAL PARAMETER	-----	150-240	3.5-0.55	<2 (mean 1.5)	3.5-0.55	35-67	80-100
PATIENT	6.7	NM	0.40	1.4	0.41	57	90
FELINE CARDIAC PARAMETERS	LA/AO (Boon)	LA/AO HEART BASE (Swe) (Abbott)	LA 2D short axis Base view (cm) (Abbott)		LVOT VEL (m/s)	RVOT VEL (m/s)	E max (m/s)
NORMAL	<1.5	<1.3	<1.2		<1.6	<1.3	<0.9
PATIENT	NM	1.3	1.3		1.4	1.0	NM

Adapted from June Boon, Veterinary Echocardiography, 1998
Abbott J & MacLean H JVIM 2006;20: 111-119, Moise et al. Am J Vet Res 47:1476, 1986. Pipers et al. Am J Vet Res 40:882, 1979.

INTERPRETED BY

Maggie Machen Lamy, DVM, DACVIM (Cardiology)

HOSPITAL NAME

Celebrie VH

REFERRING VET

Dr. Hepner

INVOICE

47505

INTERPRETATION OF THE FINDINGS & FURTHER RECOMMENDATIONS

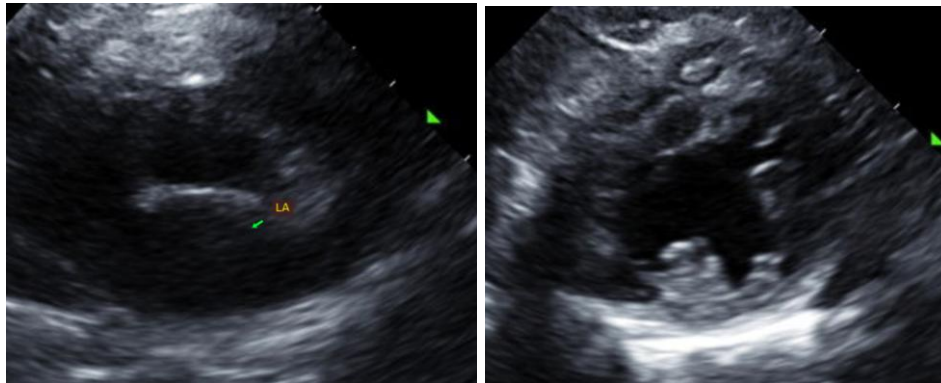
Compared to the prior study, the LA dilation has resolved, likely suggesting a transient issue. The overall appearance is of a normal geriatric heart with no LV hypertrophy or significant abnormalities identified.

Given these findings, no medications are indicated. Prognosis is good.

Anesthetic risk is considered mild. Risk for complication with steroid use or fluid administration typically follows LA dilation, which in this case is low. That being said, any cat can experience unexpected signs of intolerance and monitoring of RR/RE is advised particularly in the initiation phase.

Recommend recheck echocardiogram in 1 year to assess for any progressive issues.

IMAGES



The information and recommendations provided are based on the images presented by the referring veterinarian. No evaluation can be communicated regarding pathology that was not visible in the image/video clips provided.

Thank you for this referral. This report was generated using transcription software, and minor dictation errors may be present. If the clinical or image interpretation does not parallel your findings or if I can be of any further assistance, please contact me.

Maggie Machen Lamy, DVM
Diplomate of the American College of Veterinary Internal Medicine (Cardiology)
info@sonopath.com